

yet another investigation proving the existence of very superficially located nerve fibers in the human skin, directly

Ultrastructural Evidence for Nerve Fibers Within All Vital Layers of the Human Epidermis

in a position to react to e.g. electromagnetic fields.

Marita Hilliges,* Lixin Wang, and Olle Johansson

Experimental Dermatology Unit, Department of Neuroscience, Karolinska Institute, Stockholm, Sweden

To prove the existence of human intraepidermal nerve fibers at the electron microscopic level, we used both conventional and immunohistochemical ultrastructural techniques. Specimens were obtained from skin of the back, one of the most densely innervated areas of the human epidermis. The immunohistochemical marker protein gene product 9.5 was chosen because it is highly potent in labeling nerves. Thin nerve fibers were found in the basal, spinous, and granular layers of the epidermis with both techniques used, although it was more difficult

to identify the nervous structures with the conventional method. The nerves appeared in the intercellular spaces and contacted keratinocyte cell bodies or cilia by membrane-membrane apposition, but without any specialized structures. Nerve fibers in the very superficial part of the vital human epidermis have not been described before at the ultrastructural level. **Key words:** *intraepidermal nerves/electron microscopy/PGP 9.5 immunohistochemistry/human skin. J Invest Dermatol 104:134-137, 1995*

The intraepidermal nerve fibers have had a long and debated history [1-8]. During more than a century, investigators have attempted to evaluate the innervation of the skin using different techniques. Many of the earlier scientists used silver impregnation or methylene blue staining methods, with variable results depending on the sometimes low detectability of the fibers or difficulties in reproducibility of the techniques used.

In the last 25 years, immunohistochemistry has become widely used in innervation studies. Many scientists have revealed multiple peptide-containing nerve fibers within the human epidermis using this technique; however, the fibers were found in the basal layer only. As markers, these scientists used antibodies directed toward neuron-specific enolase, neurofilament, substance P, calcitonin gene-related peptide, neurokinin A, somatostatin, or galanin [9-18]. Based on the innervation pattern revealed by these antibodies, these markers may detect different subpopulations of the total innervation in the skin. During the last decade, the immunohistochemical marker protein gene product 9.5 (PGP 9.5), claimed to detect total innervation, has been used in innervation studies in many different organs and organ systems, such as the cardiovascular and uterine systems of the guinea pig, the human teeth, gingival epithelium, buccal mucosa, heart, and brain [19-24]. In our previous work [8], we used the indirect immunofluorescence technique at the light microscopic level and showed a rich number of fine nerves in the human epidermis using this marker. The nerve fibers were distributed throughout the strata basale, spinosum, and granulosum. The distribution and morphology were similar to

those in some of the earlier human studies using *in vitro* preparations with methylene blue or silver-impregnated nerve fibers on frozen sections [4,7].

Although light microscopy has given strong indications for the existence of free nerve endings in all the vital layers of human epidermis, ultrastructural investigations are needed to rule out other possible explanations, such as non-neuronal cell (e.g., Langerhans cell) processes. The ultrastructural studies done so far failed to show any intraepidermal nerve endings [6] or showed no nerve fibers above the germinal layer [25,26] by means of conventional electron microscopy. In this study, we investigated the human epidermis with both conventional and immunohistochemical ultrastructural techniques.

MATERIALS AND METHODS

Clinically healthy skin was obtained with punch biopsies (3 mm) from the back during local anesthesia with lidocaine. We decided to use skin from the back because the density of nerve-fiber profiles is approximately 25 times higher in skin from the back than in skin from the fingertip (Johansson O, Wang L, Hilliges M, unpublished data). The specimens intended for conventional electron microscopy were immersed in a fixative containing 4% (w/v) paraformaldehyde (freshly prepared from paraformaldehyde powder according to Pease [27]; Agar Scientific Ltd., Stansted, Essex, UK) and 5% (v/v) glutaraldehyde (Merck, Darmstadt, Germany) in a 0.08 M cacodylate buffer (pH 7.4) or in one containing 2% (w/v) paraformaldehyde and 2% (v/v) glutaraldehyde in 0.1 M phosphate buffer (pH 7.4) for 3 h at 4°C. The specimens were then rinsed in the respective buffers. Post-fixation was done in 2% (w/v) osmium tetroxide followed by dehydration in gradient ethanol. The tissue pieces were embedded in Epon 812.

Specimens intended for immunohistochemistry were immersed in 4% (w/v) paraformaldehyde, 0.1% (v/v) glutaraldehyde, and 2% (w/v) picric acid in 0.1 M phosphate buffer (pH 7.4) for 24 h at 4°C, then embedded in 10% gelatin (Sigma Chemical Co., St. Louis, MO) and cut by hand into about 100- μ m-thick sections. The sections were processed in the following solutions: 1) 3% (v/v) hydrogen peroxide (Merck) for 20 min; 2) 0.1% (v/v) Triton X-100 (Sigma Chemical Co.; see Hartman *et al* [28]) for 20 min; 3) rabbit anti-human PGP 9.5 antiserum (1:2,000) (UC, Wellow, UK) in 1% (v/v) normal goat serum overnight at 4°C; 4) biotinylated goat anti-rabbit IgG (1:200) (Vector Laboratories Inc., Burlingame, CA), for 1 h;

Manuscript received January 23, 1994, revised August 3, 1994; accepted for publication August 11, 1994.

Reprint requests to: Dr. Olle Johansson, Experimental Dermatology Unit, Department of Neuroscience, Karolinska Institute, 171 77 Stockholm, Sweden.

* Present address: Department of Oral Histology and Cellbiology, School of Dentistry, Karolinska Institute, P.O. Box 4064, 141 04 Huddinge, Sweden.

Abbreviation: PGP 9.5, protein gene product 9.5.

5) avidin-biotin-peroxidase complex (1:100) (Vector Laboratories Inc.) for 1 h; and (6) 0.05% (w/v) 3,3'-diaminobenzidine tetrahydrochloride (Sigma Chemical Co.) and 0.01% (v/v) hydrogen peroxide for 10 min. The sections were post-fixed in 1% (w/v) osmium tetroxide, dehydrated in gradient ethanol, flat-embedded in Epon 812, and evaluated in a Nikon (Tokyo, Japan) Microphot-FXA microscope using bright-field optics. Ultra-thin (silver-gold) sections were cut on a Reichert (Heidelberg, Germany) Om U3 ultramicrotome and then counterstained with 1% (w/v) uranyl acetate and 0.25% (w/v) lead citrate. The ultra-thin sections were observed and photographed in a JEOL JEM-1200 EX electron microscope. Kodak (Rochester, NY) 4489 electron microscope film was used for photography.

RESULTS

The general ultrastructural morphology did not differ between the two different fixatives used, except for a slight difference in the width of the intercellular spaces. Conventional electron microscopy revealed several cell types and, within the intercellular spaces, different types of membrane-bound profiles. One type had a more electron-dense cytoplasm than the other intercellular profiles, but was less electron-dense than the keratinocytes. These structures contained Birbeck granules and were observed in all living strata, but were somewhat more common in stratum spinosum. Another type had even less electron density, without desmosomes or Birbeck granules and with only few identifiable organelles (mitochondria and vesicles). These profiles could be observed as high as the stratum granulosum (Fig 1A). The same structures possessed PGP immunoreactivity (see below). A group of larger profiles also could be detected. These contained organelles such as mitochondria, rough endoplasmic reticulum, and some vesicles in different sizes, both clear and dense-cored.

Using the light microscope, we observed many PGP 9.5-immunoreactive fibers in the epidermis (Fig 1B). The intraepidermal nerve fibers were distributed throughout the stratum basale, spinosum, and granulosum. They appeared as free endings and mainly varicose, and entered the epidermis after originating from small nerve bundles in the upper dermis. Within the epithelium, some fibers went straight up to the superficial layers, whereas others followed a more tortuous pattern. Branching of the axon was often encountered. Ultrastructurally, PGP 9.5-positive profiles were detected within the intercellular spaces in all of the vital layers of the epidermis (Fig 1C,D). The labeled structures could be seen in close contact (membrane-membrane apposition without any specialized structures) to keratinocyte cell bodies or cilia. No such contacts could be observed between the nerves and the other epidermal cells. The morphology and distribution of the PGP 9.5-immunoreactive profiles were the same as for those profiles seen with conventional electron microscopy. The nerves generally had a fiber diameter of less than 1 μm . In one case, the most superficial profile was situated 0.4 μm from the outer surface of the vital epidermis. The immunoreactive products were mostly deposited on the membranes of the intracellular organelles. The axons were not evenly labeled; parts of the profiles could be stained very heavily whereas other parts were stained weakly.

DISCUSSION

The aim of this study was, at the ultrastructural level, to confirm or reject the existence of nerve fibers in the upper part of the living epidermis. We will therefore not discuss the cellular morphology of

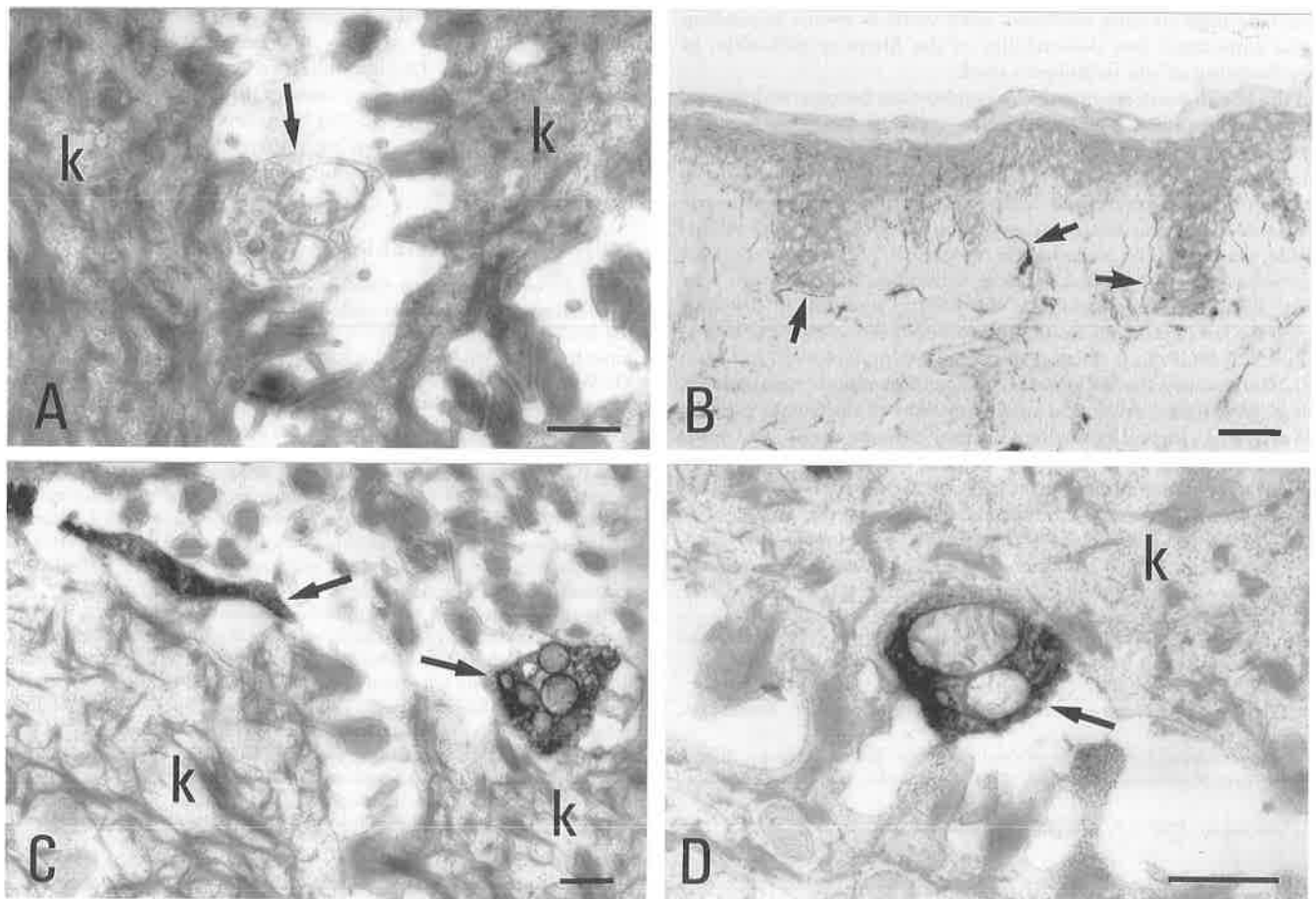


Figure 1. Nerve fibers in human epidermis. A: Micrograph of a nerve fiber profile (arrow) between keratinocytes (k) in the spinous layer of human epidermis as revealed by conventional electron microscopy. Bar, 500 nm. B: Light micrograph of PGP 9.5-immunoreactive intraepidermal nerve fibers (arrows). Bar, 100 μm . C: A PGP 9.5-positive axon and nerve ending (arrows) in the spinous layer of human epidermis as revealed by ultrastructural immunohistochemistry. Bar, 500 nm. D: Ultrastructural image of a PGP 9.5-immunoreactive nerve ending (arrow) in apposition to a keratinocyte (k). Bar, 500 nm.

keratinocytes or Langerhans cells, but instead concentrate on the membrane-bound profiles found in the intercellular spaces. One type of membrane-bound profile clearly represented processes from the Langerhans cells with a cytoplasm containing Birbeck granules. The second type, with less electron density, without desmosomes or Birbeck granules, and with few identifiable organelles, we consider to represent nerve fiber profiles. The identifiable organelles were mitochondria and vesicles. Cauna [26] also noted the frequent paucity of axoplasmic organelles in the narrow segments of varicose nerve fibers and in parts of plain endings. In the present study, the same profile type possessed PGP immunoreactivity in the immunoelectron preparations. The morphology and the lack of content of these profiles make it sometimes difficult, especially in the more superficial layers, to claim the identity of these structures using conventional ultrastructural methods alone. The third group of larger profiles contained organelles such as mitochondria, rough endoplasmic reticulum, and some vesicles in different sizes, both clear and dense-cored. The identity of these structures could be processes from other epidermal cells such as melanocytes, keratinocytes, or some other dendritic cell passing through the epidermis. These structures were not immunoreactive to PGP 9.5. The morphologic differences achieved using the two different fixatives, e.g., variations in the width of the intercellular spaces, have been described previously [29].

At the light microscopic level, the morphology and distribution of the immunoreactive fibers in the epidermis were in agreement with earlier descriptions of PGP 9.5-positive nerve fibers using dark-field fluorescence microscopy [8]. Ultrastructurally, PGP 9.5-positive profiles (axons; nerve endings) were detected within the intercellular spaces in all the vital layers of the epidermis, corresponding well to the distribution revealed at the light microscopic level. Furthermore, the sizes of the nerve profiles are in agreement with the estimations made by Novotny and Gommert-Novotny [7]. The nerve profiles could be seen in close contact to keratinocyte cell bodies or cilia. The contact was a membrane-membrane apposition without any specialized structures, and no such contacts could be observed between the nerves and the other epidermal cells. Cauna [26] also described intraepithelial axons tightly enwrapped within the folds of the epidermal keratinocytes, but only in the basal part of the epidermis.

Earlier ultrastructural studies have not been able to show, or have not reported, nerve fibers in the upper part of the human epidermis. Many reasons for this are possible: (1) The fibers are very thin, and extensive evaluation of the sections is necessary to detect them; (2) the samples investigated before were always from the skin of the finger or hand, where the density of these fibers is very low; (3) no good immunohistochemical marker for use at the ultrastructural level has been available until recently; and (4) most of the scientists working on human skin at the ultrastructural level have been more concerned with other structures in the epithelium.

Our previous findings at the light microscopic level have been confirmed in this study at the ultrastructural level. The function of these nerve fibers is not known. Although free nerve endings generally are considered to be nociceptive or thermoreceptive [30,31], the distribution pattern in the human epidermis does not entirely favor this hypothesis (Johansson O, Wang L, Hilliges M, unpublished data). The least innervated area of the human epidermis is the glabrous skin, whereas the most innervated part is skin from the back. Investigations relating morphologic and functional specializations are sparse because of methodologic difficulties. Marking the site of the receptive field of electrophysiologically characterized axons has yielded information on spot-like zones of free-ending cold fibers [32] and myelinated high-threshold mechanoreceptors in the cat [33], but such findings are compromised by the overlap of other axons supplying the same territory. In a serial sectioning experiment, Kruger *et al* [34] traced an electrophysiologically characterized polymodal axon to its terminal, which revealed a free nerve ending. This experiment was performed on the canine testis, and the traced endings were not situated within the epithelium. Furthermore, recent studies of rat hindpaw skin in sciatic-nerve-lesioned animals have revealed a dramatic reduction

of the intraepithelial nerve fibers in the skin innervated by this nerve (Stankovic N, Hildebrand C, Johansson O, unpublished data). Because the sciatic nerve includes both sensory and sympathetic axons, the intraepithelial nerve fibers in this region could be sensory as well as autonomic. In addition, C-mechanoreceptive afferents have been described in man [35], but so far the electrophysiologic data have not been combined with morphologic investigations of the terminals. Moreover, we believe that the close relation between the axons and the keratinocytes favors a functional role for the nerves on these cells, although data to support this are lacking. The possibility of neuronal-immune system interactions also cannot be excluded. The lack of functional data concerning human intraepithelial nerve fibers is evident, and more scientific efforts are needed to elucidate this enigma.

Note Added in Proof: During the completion of this article, we noted a paper (Kennedy WR, Wendelschafer-Crabb G: The innervation of human epidermis. *J Neurol Sci* 115:184-190, 1993) that supports our data.

This study has been supported by grants from the Swedish Work Environment Fund (project numbers 93-0344 and 94-0375), Nokia Monitors, Sun Microsystems AB, Radians Innova AB, Sun-Flex Datamiljö AB, Käro-Produkter AB, Magn. Bergvalls Stiftelse, the Medical Faculty of the Karolinska Institute, and by gifts from private donors.

Dr. Lixin Wang was a recipient of a scholarship from the Wenner-Gren Foundation. Dr. M. Virtanen is gratefully acknowledged for constructive criticism, Ms. Gunilla Holmkvist for excellent technical assistance, and Ms. Eva-Karin Johansson for expert secretarial work.

REFERENCES

- Langerhans P: Über die Nerven der Menschlichen Haut. *Virchows Arch* 44:325-337, 1868
- Kadanoff D: Über die intraepithelialen Nerven und ihre Endigungen beim Menschen und bei Säugetieren. *Z Zellforsch* 7:553-576, 1928
- Winkelmann RK: Some sensory nerve endings in skin: preliminary report on morphology of cutaneous sensation. *AMA Arch Dermatol* 71:373-378, 1955
- Arthur RP, Shelley WB: The innervation of human epidermis. *J Invest Dermatol* 32:397-410, 1959
- Cauna N: The effects of aging on the receptor organs of the human dermis. In: Montagna W (ed.). *Advances in Biology of Skin*, vol. 6. Pergamon Press, New York, 1964, pp 63-96
- Breathnach AS: Electron microscopy of cutaneous nerves and receptors. *J Invest Dermatol* 69:8-27, 1977
- Novotny GEK, Gommert-Novotny E: Intraepidermal nerves in human digital skin. *Cell Tissue Res* 254:111-117, 1988
- Wang L, Hilliges M, Jernberg T, Wiegleb-Edström D, Johansson O: Protein gene product 9.5-immunoreactive nerve fibres and cells in human skin. *Cell Tissue Res* 261:25-33, 1990
- Dalsgaard C-J, Jonsson C-E, Hökfelt T, Cuello AC: Localization of substance P-immunoreactive nerve fibers in the human digital skin. *Experientia* 39:1018-1020, 1983
- Dalsgaard C-J, Björklund H, Jonsson C-E, Hermansson A, Dahl D: Distribution of neurofilament-immunoreactive nerve fibers in human skin. *Histochemistry* 81:111-114, 1984
- Dalsgaard C-J, Jernbeck J, Stains W, Kjartansson J, Haegerstrand A, Hökfelt T, Brodin E, Cuello AC, Brown JC: Calcitonin gene-related peptide-like immunoreactivity in nerve fibers in the human skin: relation to fibers containing substance P-, somatostatin- and vasoactive intestinal-polypeptide-like immunoreactivity. *Histochemistry* 91:35-38, 1989
- Björklund H, Dalsgaard C-J, Jonsson C-E, Hermansson A: Sensory and autonomic innervation of non-hairy and hairy human skin: an immunohistochemical study. *Cell Tissue Res* 243:51-57, 1986
- Gibbins IL, Wattchow D, Coventry B: Two immunohistochemically identified populations of calcitonin gene-related peptide (CGRP)-immunoreactive axons in human skin. *Brain Res* 414:143-148, 1987
- Johansson O, Vaalasti A: Immunohistochemical evidence for the presence of somatostatin-containing sensory nerve fibres in the human skin. *Neurosci Lett* 73:225-230, 1987
- Johansson O, Vaalasti A, Tainio H, Ljungberg A: Immunohistochemical evidence of galanin in sensory nerves of human digital skin. *Acta Physiol Scand* 132:261-263, 1988
- Johansson O, Hilliges M, Ståhle-Bäckdahl M: Intraepidermal neuron-specific enolase (NSE)-immunoreactive nerve fibres: evidence for sprouting in uremic patients on maintenance hemodialysis. *Neurosci Lett* 99:281-286, 1989
- Vaalasti A, Tainio H, Johansson O, Rechart L: Light and electron microscopic immunocytochemical demonstration of intraepidermal CGRP-containing nerves in human skin. *Skin Pharmacol* 1:225-229, 1988

18. Weihe E, Hartschuh W: Multiple peptides in cutaneous nerves: regulators under physiological conditions and a pathogenetic role in skin disease? *Semin Dermatol* 7:284-300, 1988
19. Gulbenkian S, Wharton J, Polak JM: The visualisation of cardiovascular innervation in the guinea pig using an antiserum to protein gene product 9.5 (PGP 9.5). *J Auton Nerv Syst* 18:235-247, 1987
20. Lundberg L-M, Alm P, Wharton J, Polak JM: Protein gene product 9.5 (PGP 9.5): a new neuronal marker visualizing the whole uterine innervation and pregnancy-induced and developmental changes in the guinea pig. *Histochemistry* 90:9-17, 1988
21. Ramieri G, Anselmetti GC, Baracchi F, Panzica GC, Viglietti-Panzica C, Modica R, Polak JM: The innervation of human teeth and gingival epithelium as revealed by means of an antiserum for protein gene product 9.5 (PGP 9.5). *Am J Anat* 189:146-154, 1990
22. Hilliges M, Hellman M, Ahlström U, Johansson O: Immunohistochemical studies of neurochemical markers in normal human buccal mucosa. *Histochemistry* 101:235-244, 1994
23. Wharton J, Gulbenkian S, Merighi A, Kuhn DM, Jahn R, Taylor KM, Polak JM: Immunohistochemical and ultrastructural localisation of peptide-containing nerves and myocardial cells in the human atrial appendage. *Cell Tissue Res* 254:155-166, 1988
24. Thompson RJ, Doran JF, Jackson P, Dhillon AP, Rode J: PGP 9.5—a new marker for vertebrate neurons and neuroendocrine cells. *Brain Res* 278:224-228, 1983
25. Chouckov CN: An electron microscopic study of the intraepidermal innervation of human glabrous skin. *Acta Anat* 88:84-92, 1974
26. Cauna N: Fine morphological characteristics and microtopography of the free nerve endings of the human digital skin. *Anat Rec* 198:643-656, 1980
27. Pease DC: Buffered formaldehyde as a killing agent and primary fixative for electron microscopy. *Anat Rec* 142:342
28. Hartman BK, Zide D, Udenfriend S: The use of dopamine β -hydroxylase as a marker for the central noradrenergic nervous system in the rat brain. *Proc Natl Acad Sci USA* 69:2722-2726, 1972
29. Falck B, Andersson A, Elofsson R, Sjöborg S: New views on epidermis and its Langerhans cells in the normal state and in contact dermatitis. *Acta Dermatovener (Stockh) Suppl* 99:3-27, 1981
30. Iggo A, Andres KH: Morphology of cutaneous receptors. *Ann Rev Neurosci* 5:1-31, 1982
31. Munger BL, Ide C: The structure and function of cutaneous sensory receptors. *Arch Histol Cytol* 51:1-34, 1988
32. Hensel H, Andres KH, v Düring M: Structure and function of cold receptors. *Pflügers Arch* 352:1-10, 1974
33. Kruger L, Perl ER, Sedivec MJ: Fine structure of myelinated mechanical nociceptor endings in cat hairy skin. *J Comp Neurol* 198:137-154, 1981
34. Kruger L, Kumazawa T, Mizumura K, Sato J, Yeh Y: Observations on electrophysiologically characterized receptive fields of thin testicular afferent axons: a preliminary note on the analysis of fine structural specializations of polymodal receptors. *Somatosens Res* 5:373-380, 1988
35. Nordin M: Low-threshold mechanoreceptive and nociceptive units with unmyelinated (C) fibres in the human supraorbital nerve. *J Physiol* 426:229-240, 1990